

MASSIVE SUBCUTANEOUS EMPHYSEMA AFTER A BLUNT NECK INJURY

Mohamad I¹, Md Shukri N¹, Fauzi M H¹, Abdul Karim A H¹, Nik Hassan N F H¹

¹ Universiti Sains Malaysia

Correspondence:

Irfan Mohamad

Universiti Sains Malaysia

Email: irfankb@usm.my

ABSTRACT

Subcutaneous emphysema can occur after a breach to the air-containing space. The classical condition will be ruptured alveolus in chronic lung disease. A disruption of the upper airway such as trauma to the laryngotracheal framework may lead to similar presentation. The amount of air leak varies depending on site and size of the breach. We report a case of blunt neck trauma after a fall from bicycle, which ended with massive subcutaneous emphysema, pneumothorax and pneumomediastinum requiring intubation.

Keywords: *subcutaneous emphysema; nonpenetrating wounds; neck injuries*

INTRODUCTION

Blunt laryngeal injury can be divided into low or high velocity injury¹. Low velocity injury can be due to blow with the fist, sports injury such as karate or basketball. High velocity injury is commonly due to motor vehicle accident secondary from impact of steering wheels, handle bars and dashboard. Isolated neck injury in motor vehicle accident particularly from a bicycle fall is extremely rare. The presentation of these patients varies from only minor bruises to severe dyspnoea and massive subcutaneous emphysema.

CASE SUMMARY

A 55-year-old gentleman with no previous medical illness allegedly skidded his bicycle at the roadside. His anterior neck hit the bicycle handle bar. He presented to the Emergency Department with generalized swelling of face after 4 hours post incident. He denied having injury elsewhere. His main complaint was progressive swelling of the face, neck and body. It was worsened with bouts of coughs. Besides that, he also had persistent coughing out blood without progressive dyspnea. He denied having loss of consciousness, vomiting or bleeding elsewhere.

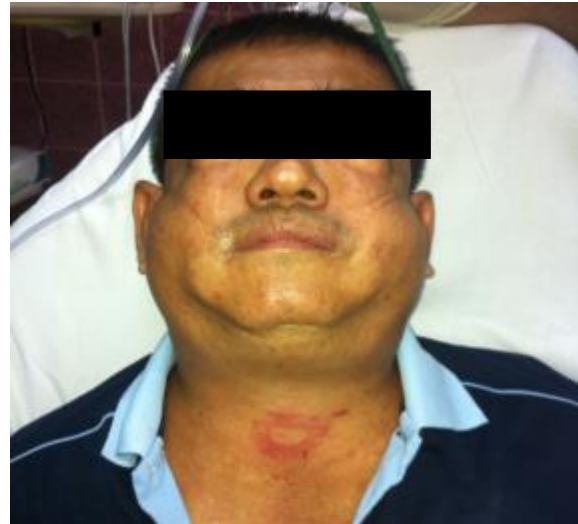

Figure 1: Massive subcutaneous emphysema up to the maxilla level at presentation, with handle bar mark at the cricoid region.

On examination, he was alert but tachypnoeic. The voice was normal. There was a mark, most likely from the bicycle handle bar, at his cricoid region (Figure 1). There was presence of massive subcutaneous emphysema involving the face, neck, chest wall, bilateral upper limbs up till fingertips and till lower abdomen without overlying skin laceration. The neck was swollen with loss of anatomical landmark. The thyroid prominence could not be palpated. Lung examination revealed equal air entry bilaterally. Oxygen saturation was decreasing despite oxygen supplement, with mild carbon dioxide retention on arterial blood gas analysis. Cervical spine radiograph revealed no fracture but massive subcutaneous emphysema was evident (Figure 2a). The chest radiograph showed bilateral pneumothorax with left lung collapse (Figure 2b).

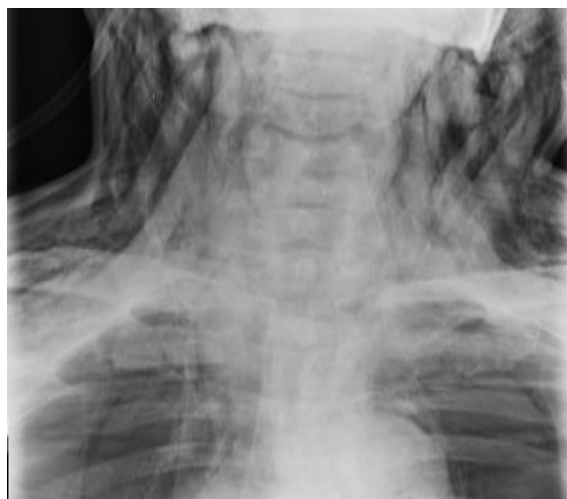

Figure 2a: Neck emphysema on neck radiograph

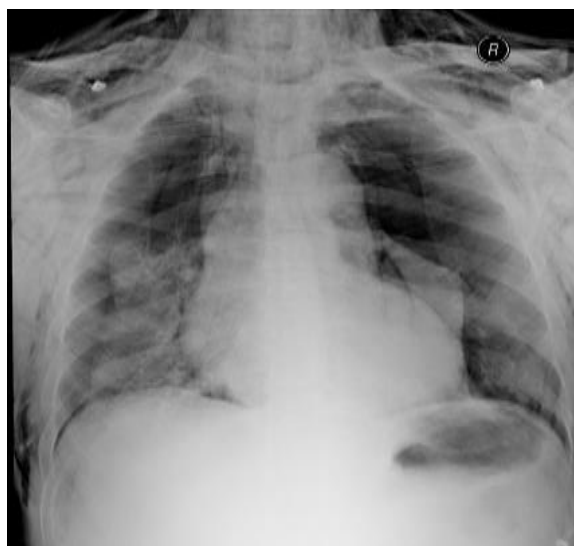

Figure 2b: There was bilateral tension pneumothoraces resulting compressive collapsed of the lung parenchymal. Pneumomediastinum and massive subcutaneous emphysema were also noted.

The patient was taken to the operating room for further evaluation and airway stabilization. Direct laryngoscopy revealed normal supraglottic structure with symmetrical vocal cord mobility. There was no oedema, hematoma or laceration at supraglottis, glottis and immediate subglottic region. Oropharyngeal intubation was

achieved with no difficulty. A CT scan of neck till abdomen showed discontinuity of left posterolateral tracheal wall at the level of C7 vertebra with massive subcutaneous emphysema (Figure 3), which was bypassed by the tube. There was also extensive bilateral pneumothorax, extensive pneumomediastinum with total collapse of left lung. The supraglottic, glottis and subglottic region were normal. Bilateral chest tubes were inserted and the patient remained stable in the ICU. The chest tube was removed on day 3 post trauma. He was extubated on the next day and was transferred to general ward. The subcutaneous emphysema completely resolved on day 4.

The patient was treated empirically with intravenous (IV) Cefuroxime 750mg 8-hourly for 1 week and IV Dexamethasone 8mg 8-hourly for 3 days. Anti-reflux agent was also given to prevent further injury to larynx. He began ambulating at this time with no sign of respiratory distress noted. He was able to take orally. There was no stridor, hoarseness of voice or dysphagia.

The patient presented to clinic for further assessment two weeks after the discharge. He was doing well at home. He denied any dyspnoea, hoarseness of voice or stridor. Repeat direct laryngoscopy revealed normal supraglottic structure with symmetrical vocal cords movement.

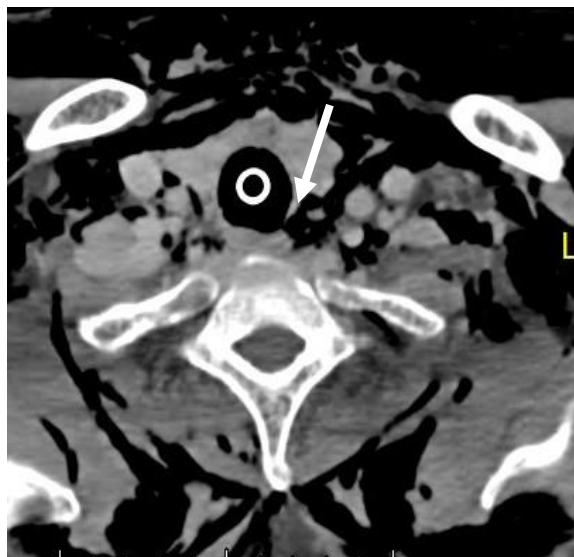


Figure 3: There was left posterolateral tracheal wall defect (Arrow), possibly the membranous portion associated with adjacent left paratracheal air collection. Massive subcutaneous and deep fascial emphysema were also noted.

DISCUSSION

This case illustrated a relatively minor blunt injury to the neck ended with massive emphysema in the subcutaneous space, mediastinum and thorax which can be fatal. In a blunt trauma, the cartilaginous laryngeal framework is compressed between the object at the cervical spine. This mechanism of injury often causes a median or paramedian vertical fracture of the thyroid and/or cricoid cartilage². In our case, airway framework breach was suspected because of presence of subcutaneous emphysema. The emphysema worsened with every bouts of cough reflecting the lesion which was located below the vocal cords. The other sign of laryngeal disruption includes hoarseness, progressive dyspnoea, neck swelling,

hemoptysis, loss of normal palpable anatomical landmark and distortion of laryngeal anatomy on laryngoscopic examination. Airway obstruction is the most serious sequel that can occur. The patients should never be left alone until it is assured by laryngoscopy or radiology imaging that there is no laryngeal or tracheal damage.

The indicators of laryngotracheal integrity breach on radiographs include abnormal tracheal outline, a pneumothorax, a pneumomediastinum or cervical emphysema³. In our case, the plain neck and chest radiographs were timely done and provide substantial points that the airway is breached and airway obstruction is pending.

Since our initial assessment during direct laryngoscopy did not reveal any injury to supraglottis and glottic regions, the upper airway is not obstructed and intubation was carried out without difficulty. Ideally the intubation should be followed by bronchoscopic examination. It is not only to see the breached part of the airway which is not possible for most of the cases as the lesion is bypassed by any artificial airway created either by means of endotracheal or tracheostomy tube. More importantly bronchoscopy is to ensure to tip of the tube is not proximal to the lesion. If the later is the case, bagging and ventilation will worsened the condition especially the pneumothorax and pneumomediastinum. Maran and Stell noted that direct laryngoscopy in laryngotracheal trauma cases can be misleading as epiglottic fracture may be missed as it is lifted upwards during the procedure⁴. The rigid instrumentation in the

traumatized larynx may also exacerbate edema and mucosal tears.

Subsequent airway management either by endotracheal intubation or tracheostomy, as well as the timing of surgery is still controversial in managing laryngotracheal trauma patients². The

decision to undertake tracheostomy should be made on the basis of the clinical state of the individual patient. The ultimate goal of treatment to the traumatized larynx is to restore airway, voice and swallowing². These were achieved in this case. He was extubated after 4 days without any residual symptoms.

REFERENCES

1. Lisa Pitkin. (2008). Laryngeal trauma and stenosis. In Scott-Brown's Otorhinolaryngology, Head and Neck Surgery (pp 2271-2285). London, Great Britain: Hodder Arnold.
2. Verschueren DS, Bell RB, Bagheri SC, Dierks EJ, Potter BE. Management of laryngo-tracheal injuries associated with craniomaxillofacial trauma. J Oral Maxillofac Surg 2006;64(2):203-14.
3. O'Keeffe LJ, Maw AR. The dangers of minor blunt trauma. J Laryngol Otol 1992;106:372-3.
4. Maran AG, Stell PM. Acute laryngeal trauma. Lancet 1970;2(7683):1107-10.